www.roavs.com EISSN: 2223-0343
RESEARCH OPINIONS IN ANIMAL & VETERINARY SCIENCES

Management of complete and partial ankyloglossia in Kangal shepherd dogs

Fahrettin Alkan[1*], Yılmaz Koç[1], Cafer Tepeli[2], Hasan Albasan[3] and Semih Altan[4]

[1]Faculty of Veterinary Medicine, Department of Surgery, Selcuk University, Konya, Turkey
[2]Faculty of Veterinary Medicine, Department of Animal Science, Selcuk University, Konya, Turkey
[3]Faculty of Veterinary Medicine, Department of Internal Medicine, Ankara University, Ankara, Turkey
[4]Faculty of Veterinary Medicine, Department of Surgery, Dicle University, Diyarbakır, Turkey

Abstract

The objective of this paper was to assess the clinical findings of ankyloglossia and its management in Turkish shepherd dogs (Kangal). Sixteen Kangal dogs were evaluated for either ventral complete ankyloglossia or ventral partial ankyloglossia. Lingual frenuloplasty or lingual frenulotomy was applied to correct ankyloglossia in dogs. Surgical management of dogs with complete or partial ankyloglossia resulted in total correction of this anomaly. Physical growth of treated animals rapidly progressed and the weight of animals elevated within the normal range. In conclusion, Kangal shepherd puppies should be assessed for the congenital anomaly of ankyloglossia. Although this anomaly is not fatal, dogs could be treated with either lingual frenuloplasty or lingual frenulotomy.

Keywords: Ankyloglossia; dog; frenulotomy; frenuloplasty; congenital disorders; kangal

To cite this article: Alkan F, Y Koç, C Tepeli, H Albasan and S Altan, 2013. Management of complete and partial ankyloglossia in kangal shepherd dogs. Res. Opin. Anim. Vet. Sci., 3(12), 462-465.

Introduction

In the oral cavity of companion animals, observation of many congenital anomalies as palatoschisis, astomia, aglossia, microglossia, ankyloglossia, lingua bifida or duplicities lingua at the birth and/or right after birth have been reported (Harvey, 1993; Kilic and Sarierler, 2004; Grundmann and Hofmann, 2006).

Ankyloglossia is a congenital anomaly, known as tongue tie in human and veterinary medicine that was rarely seen in dogs. Ankyloglossia or tongue tie was defined as partial or complete fusion between the tongue and the base of the oral cavity (Wolff, 1980; Mouli, 1993; Ozaydin et al., 2000; Lalakea and Messner, 2003; Naimer et al., 2003; Temizsoylu and Avki, 2003; Morita et al., 2004). This fusion develops due to the shortage or developmental anomaly of connective tissue known as the lingual frenulum which normally lies as a thin longitudinal line under the midline of the tongue. In a normal lingual frenulum, apex of the tongue can be moved freely in the mouth and root of the tongue is stably fixed (Temizsoylu and Avki, 2003; Kilic and Sarierler, 2004; Grundmann and Hofmann, 2006).

In ankyloglossia, the tongue could not be freely moved when complete fusion with the floor of oral cavity is present. Depending on the degree of the fusion, the mobility of the tongue is limited. When the tongue is pulled out of mouth, the tongue could not go any further beyond the gingiva of mandibular incisors. Tip of the tongue usually has a shape of the letter “W”. Attempts to protrude the tongue out of mouth are in vain. When the mouth is open, the tip of the tongue could not reach to the upper palate (Ozaydin et al., 2000; Temizsoylu and Avki, 2003; Kilic and Sarierler, 2004; Grundmann and Hofmann, 2006).

Ankyloglossia prevents partially or completely movement and functions of the tongue, and results in difficulties of suckling, swallowing and voice in puppies, and injuries the nipples of mothers. As with aging, problems in movement of foods in the mouth, chewing and passing food into the esophagus can be occurred. Therefore, holostonosis and cavities in teeth

***Corresponding author:** Fahrettin Alkan, Faculty of Veterinary Medicine, Department of Surgery, Selcuk University, Konya, Turkey.

can eventually be observed due to accumulation of foods in teeth and periodontal tissue (Ozaydin et al., 2000; Lalakea and Messner, 2003; Naimer et al., 2003; Kilic and Sarierler, 2004). When ankyloglossia is determined right after birth, but without causing feeding problems, surgical intervention can be postponed for a certain period of time. If aforementioned problems were observed, the fusion in the tongue should be taken care immediately with either lingual frenuloplasty or lingual frenulotomy methods to free the tongue (Naimer et al., 2003; Temizsoylu and Avki, 2003; Grundmann and Hofmann, 2006).

The purpose of present study was to assess clinical findings and the outcome of treatment of ankyloglossia in Kangal shepherd dogs.

Materials and Methods

The materials of this study consisted of 14 puppies and 2 adults of Kangal shepherd dogs. Of 16 kangal dogs, 13 belonged to the farm of veterinary school, and remaining three were client-owned dogs presented to the veterinary teaching hospital. History, physical and oral examinations were obtained about all dogs.

Lingual frenuloplasty for partial ankyloglossia and lingual frenulotomy for complete ventral ankyloglossia were applied for the treatment under general anesthesia with injectable anesthetic agents.

Food was withheld from dog for 12 hours prior to anesthesia. Dogs were premedicated with atropine sulfate (0.04 mg/kg, S/C, Atropin®, Vetaş, Turkey) and medetomidine hydrochloride (0.02 mg/kg, I/M, Domitor®, Pfizer, Turkey) and anesthetized with ketamine hydrochloride (20 mg/kg, I/M, Ketasol® %10, Interhas, Turkey). For preoperative antibiotherapy, 30 minutes prior to the first incision, cefazolin sodium (22 mg/kg, I/V, Cefamezin®, Eczacıbaşı, Turkey) was administered. Ringer lactate solution (20 mL/kg/h, I/V, Biofleks Ringer Laktat®, Osel İlaç, Turkey) was administered during the anesthesia. They were then positioned in lateral recumbency, while their head was lowered compared to their body in position. The mouth was held open with cloth bands to expose the tongue, and the oral cavity was flushed with diluted povidone iodine solution. Postoperative analgesia was provided with flunixin meglumine (1 mg/kg I/V, Fulimed®, Alke, Turkey) daily for 3 days.

Lingual frenuloplasty was performed to free the apex in partial ankyloglossia, by sectioning the tissue band with two incisions between the tongue and the floor of the oral cavity with a pair of fine scissors. First incision started from apex of the tongue and continued caudally along the ventral surface of the tongue (Fig. 1). Second incision continued through the floor of the oral cavity. Then these two incisions were connected at the level where the lingual frenulum would normally start. Surgeons paid attention not to interfere with lingual frenulum and salivary gland ducts. Therefore, the tongue was kept tensed upwards and slightly fronted to determine the junction between the band tissue and lingual frenulum. Bleeding was controlled with an electrocauter. The incisions in the sublingual and oral cavity were sutured with continuous simple suturing technique with 3/0 polyglactine 910 (Coated Vicryl®, Ethicon, UK).

Lingual frenulotomy was performed to correct the complete ventral ankyloglossia by electrocauterization (Fig. 2). While apex of the tongue was kept tense upwards with the tongue pens, electrocauterization was performed to free the tongue from a point close to apex of tongue where the fusion ends to the frenulum lingua. Bleeding was controlled with an electrocauter, and then the procedure was completed by applying 30% glycerin iode (majistral drug for mucosal antisepsy) to the oral cavity.

Owners were instructed that animals should be fed with liquid food for 5 days, and patients were prescribed with cefazolin sodium (22 mg/kg, I/M, every 12 hours) for 5 days and oral antiseptic of 30% glycerin iode for three days. Animals were followed up for 2 months after the surgical procedure.

Results

Out of 16 animals, eight dogs (six puppies and two adults) were diagnosed with ankyloglossia. Moreover, five of eight dogs had complete ventral ankyloglossia while the remaining three dogs had ventral partial ankyloglossia (Table 1).

Table 1: Age, gender, and body weight of the affected dogs with ankyloglossia

Dogs	Age (month)	Gender	Body weight (kg)	Diagnosis
1[a]	2	Male	3.6	Complete ventral ankyloglossia
2[a]	2	Female	2.9	Complete ventral ankyloglossia
3[a]	2	Female	3.3	Complete ventral ankyloglossia
4[b]	2	Male	2.8	Complete ventral ankyloglossia
5[b]	2	Female	3.4	Complete ventral ankyloglossia
6	6	Female	14.4	Apex free partial ankyloglossia
7	18	Female	30.3	Apex free partial ankyloglossia and lingua bifida
8	23	Male	38.5	Apex free partial ankyloglossia and lingua bifida

a: puppies with complete ventral ankyloglossia are siblings; b: puppies with complete ventral ankyloglossia are siblings.

Case history revealed that 13 puppies belonged to the farm of veterinary school (Table 1). Eight were sibling from a mother and remaining five were sibling from another mother. Moreover, those two mothers were also sibling and had a history of ankyloglossia when they were born. Of 13 puppies, five were diagnosed with complete ankyloglossia (three from eight siblings and two from five

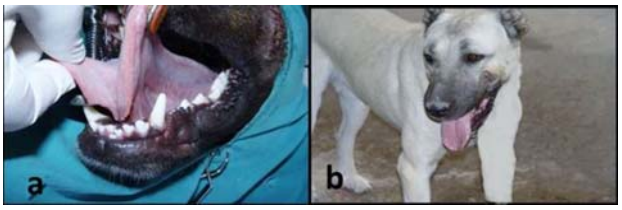

Fig. 1: (a) Apex free partial ankyloglossia and lingua bifida in a six-month-old Kangal puppy showing fixed tongue (b) The same dog after frenuloplasty showing freely movable tongue

Fig. 2: (a) Complete ventral ankyloglossia in a two-month-old kangal puppy showing fixed tongue (b) The same pupy after frenulotomy with electrocauter

siblings). Of these five puppies with complete ankyloglossia, three were female and two were male. Physical examination of 13 puppiess belong to the farm revealed that the growth of five affected puppies was poor compared with healthy siblings. The average weight of puppies with ankyloglossia was determined as 3.2 kg while weight of healthy siblings was 5.6 kg.

Furthermore, these five puppies were unable to protrude their tongues properly; and therefore, they were unable to reach the upper palate with their tongue. When they tried to protrude their tongue, it was turned backwards and the tip of the tongue had a shape of the letter "W". The tongues of these puppies could not be taken out even with a manual manipulation with hand. In addition, these puppies were also unable to suck their mothers.

Client-owned three dogs (one male, two females) had a history of slow development and consistently spilling out food and water when they tried to eat or drink. These three dogs were not sibling. Physical examination of these three dogs revealed continuous drooling of saliva and inability of these dogs to protrude their tongues properly. Unlike the aforementioned puppies, the tongue of these animals was only attached to the base not the apex of mouth with a thin membrane like tissue. Besides these findings, it was also determined that two of these three dogs had a 2-cm cleft at the tip of the tongue (lingua bifida).

Following up of all eight dogs for two months after surgical procedure indicated that there were no complications. Moreover, animals were observed with full mobility of their tongue without any limitations or problems; and therefore, normal development of dogs was observed.

Discussion

Although congenital tongue anomalies like aglossia, microglossia, macroglossia or ankyloglossia had rarely been reported in dogs, ankyloglossia in Kangal shepherd dogs, a commonly raised domestic breed of Anatolia, was reported in recent years (Temizsoylu and Avki, 2003; Kilic and Sarierler, 2004; Grundmann and Hofmann, 2006). Findings of the present study were consistent with recent reports. Therefore, it could be stated that this anomaly is common in Kangal shepherd dogs. Description of clinical findings of these cases with appropriate treatment methods will be beneficial to practicing veterinarians.

Ankyloglossia defined as a combination of the congenital anomalies characterized by limited mobility of the tongue. In the present study, five complete ventral ankyloglossia and three partial ankyloglossia with free apex (2 with bifida lingua) were observed without any other anomalies. In the veterinary literature, complete ventral ankyloglossia was reported in three Kangal shepherd dogs (Temizsoylu and Avki, 2003); partial ankyloglossia was reported in a calf (Mouli, 1993), a goat (Nair and Bandopadhyay, 1994), a dog (Grundmann and Hofmann, 2006) and a camel (Anwar and Purohit, 2012). Complete ventral ankyloglossia with 3-cm bifida lingua was reported in Kangal shepherd dogs (Ozaydin et al., 2000).

In normal dogs, the tongue is attached to the mouth with a plicate leaf called frenulum lingua, and it is not connected to apex; therefore, the tongue could move freely (Harvey, 1993; Temizsoylu and Avki, 2003; Kilic and Sarierler, 2004; Grundmann and Hofmann, 2006). In ankyloglossia cases, frenulum lingua is usually connected to the gingiva of the mandibular incisors. Therefore, movement of the tongue is limited depending on the degree of fusion, and dogs are unable to protrude their tongues properly. In the present study, dogs with complete ankyloglossia were unable to move their tongue. This finding was consistent with previous reports (Ozaydin et al., 2000; Temizsoylu and Avki, 2003; Kilic and Sarierler, 2004; Grundmann and Hofmann, 2006).

Although incidence of ankyloglossia in humans was reported as a range of 0.02-4.80%, there were no available reports about the incidence of this anomaly in animals (Naimer et al., 2003; Grundmann and Hofmann, 2006). Only one report stated that the incidence of ankyloglossia in Kangal shepherd dogs in farms was 7.97% (Tepeli, 2003). High rate of incidence of ankyloglossia in Kangal shepherd dogs could be explained by using related female and male dogs even those had ankyloglossia for breeding. In this respect, the majority of the evaluated puppies in this study were sibling; moreover, their parents were also sibling with history of this anomaly. It was reported that a mutation in T genes of the mother or exposure of the mothers to teratogenic chemicals during pregnancy can

lead to congenital ankyloglossia (Naimer et al., 2003; Morita et al., 2004). In this study, genetic analysis of the cases was not evaluated. Therefore, presence of ankyloglossia could not be explained by breed predisposition in this study.

Tongue is a moveable organ in the oral cavity. It plays an efficient role in taking, moving and sending food to the esophagus. It also has a role in maintaining oral hygiene and in producing voice. When a congenital anomaly like ankyloglossia is present, the tongue became disable to complete one or more aforementioned functions (Ozaydin et al., 2000; Lalakea and Messner, 2003; Temizsoylu and Avki, 2003; Kilic and Sarierler, 2004; Morita et al., 2004; Grundmann and Hofmann, 2006). It was consistent with the findings of the present study that dogs with ankyloglossia had difficulties in taking foods and water, and had bad growth. After surgical treatment, puppies and dogs started eating and drinking well, and consequently they gained weight.

Ankyloglossia is treated with either lingual frenuloplasty or lingual frenulotomy under general anesthesia. The choice of the surgical technique depends upon the degree of ankyloglossia. In this respect, local and inhalation anesthesia could not be efficient in both lingual frenuloplasty and lingual frenulotomy in dogs. Therefore, injectable general anesthesia for these procedures was recommended in this study. Similar recommendations was mentioned by (Naimer et al. 2003; Temizsoylu and Avki, 2003; Grundmann and Hofmann, 2006).

In conclusion, congenital anomalies like ankyloglossia can be observed in areas where Kangal shepherd dogs are commonly bred. These anomalies can be treated without any complication with either lingual frenuloplasty or lingual frenulotomy procedures under general injectable anesthesia. Dogs, puppies born with this anomaly and their parents should not be considered for breeding. Future genetic studies should be performed in regarding the breed predisposition.

References

Anwar, S. and Purohit, G.N. 2012. Ankyloglossia and its surgical correction by frenuloplasty in a she-camel calf (Camelus dromedarius). *Open Veterinary Journal*, 2: 23-25.

Grundmann, S. and Hofmann, A. 2006. Ankyloglossie bei einem anatolischen hirtenhund (kangal). *Schweizer Archiv für Tierheilkunde*, 148: 417-420.

Harvey, C.E. 1993. Oral cavity, in: Slatter. D.H. (editor), Textbook of Small Animal Surgery. 1st edition. Saunders, Philedelphia, Pp: 510-520.

Kilic, N. and Sarierler, M. 2004. Surgical correction of a congenital ankyloglossia in an anatolian shepherd dog. *Indian Veterinary Journal*, 81: 1271-1272.

Lalakea, M.L. and Messner, A.H. 2003. Ankyloglossia: the adolescent and adult perspective. *Otolaryngology Head and Neck Surgery*, 128: 746-752.

Morita, H., Mazerbourg, S., Bouley, D.M., Luo, C.L., Kawamura, K., Kuwabara, Y., Baribault, H., Tien, H. and Hsueh, A.J.W. 2004. Neoanatal lethality of LGR5 null is associated with ankyloglossia and gastrointestinal distention. *Molecular and Cellular Biology*, 24: 9736-9743.

Mouli, S.P. 1993. Surgical correction of congenital glossa frenata in ongole breed bull calf. *Indian Veterinary Journal*, 70: 449-450.

Naimer, S.A., Biton, A., Vardy, D. and Zvulunov, A. 2003. Office treatment of congenital ankyloglossia. *Medical Science Monitor*, 9: 432-435.

Nair, N.R. and Bandopadhyay, A.C. 1994. Thyroglossal cyst below the base of tongue with ankyloglossia in a kid. *Indian Veterinary Journal*, 71: 279.

Ozaydin, I., Demirkan, I., Ozba, B. and Cihan, M. 2000. A case of congenital permanent frenulum linguae and lingua bifida (bifid tongue) in an Anatolian shepherd (kangal) dog. *Kafkas Universitesi Veteriner Fakültesi Dergisi*, 6: 107-109.

Temizsoylu, M.D. and Avki, S. 2003. Complete ventral ankyloglossia in three related dogs. *Journal of the American Veterinary Medical Association*, 233: 1143-1145.

Tepeli, C. 2003. Some genetic disorders in kangal Turkish shepherd dogs. Proceedings of the 1st International Symposium of Kangal Dog. Sivas, Turkey, Pp: 91-93.

Wolff, A. 1980. Tongue-tie in a dog? *Canine Practice*, 7: 6.