



Research article

Studies on indigestible foreign bodies in goats slaughtered at Morogoro Municipal slaughterhouse, Tanzania

Makungu M^{1*} and Nonga HE²

¹Department of Veterinary Surgery and Theriogenology; ²Department of Veterinary Medicine and Public Health, College of Veterinary Medicine and Biomedical Sciences, Sokoine University of Agriculture, P. O. Box 3021, Chuo Kikuu, Morogoro, Tanzania

Table with 2 columns: Article history (Received, Revised, Accepted) and Abstract (This cross sectional study was conducted in October and November 2017 to investigate the occurrence of indigestible foreign bodies in goats slaughtered at Morogoro Municipal slaughterhouse, Tanzania. During ante-mortem examination of goats, the breed, sex, age, origin and the general body conditions were recorded. After slaughter and evisceration, the set of stomachs of 119 goats examined for the presence of indigestible foreign bodies. The results indicated that most of the slaughter goats were local breed (90.8%), female (66.4%), had age >2 years (63.0%), had originated from Dakawa (42.9%) and their general body condition was moderate (65.5%). Out of 119 goats, 22 (18.5%) had different kinds of indigestible foreign bodies in their rumen or rumen and reticulum. A significantly (P<0.05) high proportion of animals with poor body condition (40.0%) had indigestible foreign bodies compared to those with good body condition (9.7%). The observed indigestible foreign bodies were plastic bags (77.3%), maize cobs (13.6%), clothing material (4.5%), hairballs (9.1%), stones (4.5%) and fruit seeds (9.1%). Further, a greater proportion (72.7%) of indigestible foreign bodies, were encountered in the rumen. This study found that the ingestion of indigestible foreign bodies is common in goats slaughtered at the Morogoro Municipal slaughterhouse as a result of widespread use with improper disposal of plastic bags. This may cause significant losses in the livestock production. Therefore, it is recommended that plastic bags should be properly disposed of and appropriate policies for solid waste management should be implemented. Keywords: Foreign bodies; Goat; Slaughterhouse; Tanzania)

To cite this article: Makungu M and HE Nonga, 2018. Studies on indigestible foreign bodies in goats slaughtered at Morogoro Municipal slaughterhouse, Tanzania. Res. Opin. Anim. Vet. Sci., 8(1): 13-18.

Introduction

In Tanzania, goats are mainly kept for meat production and their meat ranks second to beef in sales and consumption (Chenyambuga et al., 2012). They are also kept as pets and for manure, milk, and skin production (Peacock, 2005; Baillie and Anzuino,

2006; Onditi et al., 2007). Additionally, they are used for teaching and research (Fulton et al., 1994; Mpanduji et al., 2000). On average 2.71 million goats are slaughtered in Tanzania annually (NBS, 2012). Many households especially in rural areas keep goats and sheep as among the sources of livelihood (URT, 2012).

*Corresponding author: Makungu M, Department of Veterinary Surgery and Theriogenology, College of Veterinary Medicine and Biomedical Sciences, Sokoine University of Agriculture, P. O. Box 3020, Chuo Kikuu, Morogoro, Tanzania; E-mail: modesta_makungu@yahoo.com

The importance of goat farming has increased due to their fast economic return (Hozza et al., 2014). Goat is the main supplier of dairy and meat product for rural people and is regarded as “the cow of the poor people” (Haenlein, 2004; Chenyambuga et al., 2012). They provide more meat and milk per unit live weight per year than other large ruminants (Hozza et al., 2014). The demand of goat’s meat has increased in urban areas due to its palatability and delicacy (Chenyambuga et al., 2012). Similarly, goat milk has gained popularity since has better digestibility, buffering capacity, alkalinity and certain therapeutic values (Kumar et al., 2012). The demand for goat milk has also increased due to the growing population of people, affliction of people with cow milk allergies and other gastro-intestinal ailments and connoisseur interest in goat milk products especially yoghurt and cheese (Haenlein, 2004).

The population of goats in Tanzania is approximately 16.7 million (MLFD, 2015) of which 98% are the indigenous type belonging to the small East African breed which are raised by small scale farmers in particular pastoralist and agro pastoralists (Chenyambuga et al., 2012). They are widely distributed in all agro-ecological zones of country and have good tolerance to diseases, heat and drought (Chenyambuga et al., 2012). The main limiting factors to goat production in Tanzania are shortage of grazing land, feed and water during dry season and animal health related problems (Chenyambuga et al., 2012). Diseases and conditions involving the digestive system such as indigestible foreign bodies (Ghurashi et al., 2009; Fromsa and Mohammed, 2011; Otsyina et al., 2015), helminthiosis (Chenyambuga et al., 2012; Ng’umbi et al., 2015), hydatidosis (Nonga and Karimuribo, 2009), megaesophagus (Parish et al., 1996; Mozaffari and Vosough, 2007) and neoplasia (Löhr, 2013) have been reported in goats.

Ingestion of non-metallic indigestible foreign bodies in ruminants lead to loss of production and mortality as a result of decreased feed intake, weight loss, electrolytes and acid base abnormalities, and rumen impaction (Constable et al., 2017). Environmental contamination with indigestible foreign bodies is observed in different urban areas and cases of ingestion of indigestible foreign bodies in goats have been observed in Tanzania which contributes to economic losses (Sokoine University of Agriculture animal hospital unpublished data, 2017). The objective of this study was to investigate the occurrences of indigestible foreign bodies in goats slaughtered at Morogoro Municipal slaughterhouse to determine the magnitude of condition for appropriate control measures.

Materials and Methods

Study area

This study was conducted at the Morogoro Municipal slaughterhouse, in Morogoro region. The

Morogoro Municipality lies between latitude 5°7' to 10°00' South of the Equator and longitude 35°6' to 39°5' East of Greenwich (Nonga et al., 2010). The region receives an annual average rainfall of 600 mm to 1200 mm (MPEE, 2006). Morogoro Municipality is situated 200 km west of Dar es Salaam and has an altitude of 500 m to 600 m above sea level (Muhairwa et al., 2007; Nonga et al., 2010). On average 10 to 15 goats are slaughtered per day and originate mainly from Dakawa, Melela and Makunganya.

Study design

This was a cross sectional study which was conducted between October and November 2017 at the Morogoro Municipal slaughterhouse which slaughters up to 15 goats per day. All animals slaughtered during each visit at the slaughterhouse were inspected for the presence of indigestible foreign bodies in the stomachs during postmortem examination.

The source of the animal, grazing system, breed, age, sex and body condition score was recorded. The source of the animals and the grazing system were explored from the animal owners. The body condition score of the animal was recorded as good, moderate and poor based on appearance of the animal and manual palpation of the transverse processes and dorsal spines of the lumbar vertebrae as described previously (Negash et al., 2015). The age of the animal was estimated by dentition as previous described (Wilson and Durkin, 1984; Matika et al., 1992) and was categorized as ≤ 2 years and > 2 years.

Postmortem inspection of indigestible foreign bodies was performed after the goat was slaughtered and eviscerated. The set of stomachs was put on clean plastic sheet spread on the floor and straightened to clearly display the rumen, reticulum, omasum and abomasum. Each stomach was separated, and then longitudinally sliced. The contents of each stomach part were carefully emptied while inspecting for any material which is not of animal feed and classified as indigestible foreign body. Unclearly identified materials were washed with tap water for clearly visibility.

Statistical analysis

Data collected was entered into the Microsoft Office Excel spread sheet (Microsoft 2010) and analyzed using Epi Info™ version 7.2.2.2 (Centers for Disease Control and Prevention, Atlanta, 2017). Percentages for categorical variables were calculated and chi-square test was used for comparison. Statistically significant difference was accepted at a probability of $p < 0.05$.

Results

A total of 119 goats were examined for the presence of indigestible foreign bodies at the Morogoro

Table 1: Occurrence of indigestible foreign bodies in different categories of goats slaughtered at Morogoro Municipal slaughterhouse (n=119)

Parameter	Category	Animals examined	Animals with indigestible foreign bodies	Percent (%)	Odds Ratio	95% CI	<i>p-value</i>
Breed	Cross	11	1	9.1	2.4138	0.2926-	0.2256
	Local	108	21	19.4		19.9131	
Sex	Female	79	13	16.5	1.4739	0.5694-	0.2166
	Male	40	9	22.5		3.8152	
Age	≤ 2	44	6	13.6	1.7175	0.6175-	0.1552
	> 2	75	16	21.3		4.7774	
Body condition	Poor	10	4	40.0	6.2222	1.0950-	0.02650*
	Good	31	3	9.7		35.3565	
	Moderate	78	15	19.2	2.2222	0.5953-	
	Good	31	3	9.7		8.2948	

*Statistically significant.

**Fig. 1: A photograph of small East African goats from the Morogoro Municipal slaughterhouse, Tanzania.****Table 2: Frequency of indigestible foreign bodies in goats slaughtered at Morogoro Municipal slaughterhouse.**

Type of foreign body	Number (%) of goats with foreign body
Plastic bags	17 (77.3)
Maize corns	3 (13.6)
Stones	1 (4.5)
Clothing material	1 (4.5)
Hairballs	2 (9.1)
Fruit seeds	2(9.1)

Municipal slaughterhouse. The majority of the slaughtered goats originated from Dakawa (42.9%), Melela (37.8%) and Makunganya (9.2%). The rest, 10.1% originated from areas within the Morogoro Municipality i.e. Tungi, Mkundi, Kilakala and Kihonda. Of the 119 goats examined, 79 (66.4%) were females (Table 1). The greater proportion (90.8%) of goats examined for the presence of indigestible foreign bodies was local breed belonging to small East African goats (Fig. 1). The rest 9.2% were crossbred of Boer and Small East African goats (Table 1). All goats were extensively grazed.

Out of 119 goats examined, 22 (18.5%) had different kinds of indigestible foreign bodies in their

rumen or rumen and reticulum (Fig. 2). Of the 119 animals examined, 26.1%, 65.6% and 8.4% had good, moderate and poor body condition score, respectively (Table 1). Most of the indigestible foreign bodies (40%) were observed in animals with poor body condition score. Statistically significant difference ($P < 0.05$) was observed between animals with poor body condition and those with good body condition (Table 1). There was no statistically significant ($P > 0.05$) difference which was observed among the different breed, sex and age categories (Table 1).

Indigestible foreign bodies observed in this study were plastic bags (77.3%, $n=17$), maize corns (13.6%, $n=3$), clothing material (4.5%, $n=1$), hairballs (9.1%, $n=2$), stones (4.5%, $n=1$), and fruit seeds (9.1%, $n=2$) (Table 2 & Fig. 2). A mixture of three different indigestible foreign bodies found in two goats. A greater proportion (72.7%) of indigestible foreign bodies which were encountered in this study was located in the rumen (Fig. 3).

Discussion

In this study it was found that out of 119 slaughtered goats at the Morogoro Municipal slaughterhouse, 22 (18.5%) had indigestible foreign bodies in their fore-stomachs. The occurrence of indigestible foreign bodies obtained in this study is lower than the previously reported in southern Darfur (Ghurashi et al., 2009), and eastern Ethiopia (Negash et al., 2015), which were 84%, and 59.3%, respectively. However, it was higher than the reported incidence rates in Kenya (Otsyina et al., 2015), Ghana (Atawalna et al., 2015) and in other parts of Ethiopia (Fromsa and Mohammed, 2011; Mekuanint et al., 2017).

The variation in the occurrences of indigestible foreign bodies in reported areas may be due to variations in seasons, climatic conditions, husbandry and waste management practices in which the studies were conducted. Additionally, the extent of pollution of grazing lands with indigestible materials may also




Fig. 2: Different types of indigestible foreign bodies in goats slaughtered at Morogoro Municipal slaughterhouse, Tanzania. A: Plastic bags. B: Fruit seeds from avocado (white arrow) and palm (asterisks).

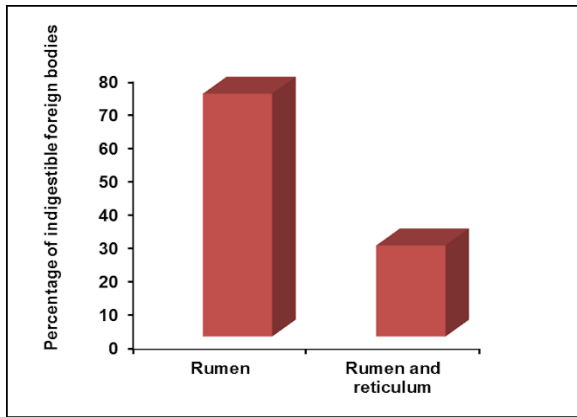


Fig. 3: The proportion of indigestible foreign bodies in different compartments in goats slaughtered at Morogoro Municipal slaughterhouse, Tanzania.

contribute to the variations. Previous studies (Ghurash et al., 2009; Mushonga et al., 2015) reported that indigestible foreign bodies in ruminants are frequently encountered during hot dry seasons and in desert areas. Poor husbandry management practices such as inadequate supplementation of minerals, vitamins and forages especially in dry seasons may predispose ruminants to ingestion of indigestible foreign bodies as a result of pica. Improper waste management practices increase the chances of contamination or pollution of grazing lands with indigestible foreign bodies which is a big problem in extensive grazed ruminants (Ghurashi et al., 2009; Negash et al., 2015). The examined goats during the current study were extensively managed and they don't receive any supplementations such that they likely succumbed into pica which made them to ingest indigestible materials.

Indigestible foreign bodies once ingested may cause anorexia and interference with flow of ingesta and absorption of Volatile Fatty Acids (VFA) which

results in weight loss (Igbokwe et al., 2003; Baillie and Anzuino, 2006; Ban Ismail et al., 2007; Mozaffari et al., 2009; Habasha and Yassein, 2014; Berrie et al., 2015). Anorexia may result due to the presence of the foreign body itself in the rumen occupying most of the rumen leaving little space for food (Baillie and Anzuino, 2006; Mozaffari et al., 2009). Further, the physical presence of the foreign body mass and the stretch of the cranial sac of the rumen can stimulate the ventromedial hypothalamus and satiety center leading to loss of appetite (Mozaffari et al., 2009). This may explain the significant higher occurrence of indigestible foreign bodies in goats with poor body condition than those with good body condition obtained in this study. However, other factors such as nutritional deficiencies, gastrointestinal parasites, and old age may have contributed to the poor body condition of the animals (Baillie and Anzuino, 2006; Bwatota et al., 2018).

Among different kinds of indigestible foreign bodies observed in this study, plastic bags were the most frequently encountered which indicates there is a wide spread use of plastic bags with improper disposal in urban and periurban areas of Morogoro region. Since plastic bags are non-biodegradable, they persist in the environment for a long time and likely to be ingested by ruminants. Plastic bags are commonly used in Morogoro for packaging of different items including food. Goats may be attracted to ingestion of plastic bags because of salty taste, sugar, spices or remnants of food on them (Atawalna et al., 2015). Ingestion of plastic bags in goats has also been reported to be a problem in other countries in Africa such as Kenya (Otsyina et al., 2015), Ghana (Atawalna et al., 2015), Ethiopia (Tiruneh and Yesuwork, 2010; Negash et al., 2015) and Sudan (Ghurashi et al., 2009).

Hairballs have been reported in various species including small ruminants, cattle, cats, rabbits and

humans (Abutarbush and Radostits, 2004; Baillie and Anzuino, 2006; Muhammad et al., 2011). In ruminants they occur due to excessive grooming or sucking of pen mates as a result of behavioral cause or skin diseases (Abutarbush and Radostits, 2004; Baillie and Anzuino, 2006; Muhammad et al., 2011; Constable et al., 2017; Bwatota et al., 2018). Once ingested in ruminants, hair form oval bodies (balls) as a result of churning and rolling movements of the rumen (Abutarbush and Radostits, 2004). The presentation of animals with hairballs varies from asymptomatic to anorexia, weight loss, choke and gastrointestinal obstruction (Abutarbush and Radostits, 2004; Baillie and Anzuino, 2006; Muhammad et al., 2011). Ingested hairs in ruminants are known to cause rumenitis, abomasitis, mucosal erosions, and ulcers (Tanimotyo et al., 1994).

The current study also established that most of the indigestible foreign bodies (72.7%) were found in the rumen probably due to its larger volume compared to other compartments. Studies also show that almost all ingested feed especially of low density settles in the rumen where they keep on causing different problems including rumenitis (Ghurashi et al., 2009; Tesfaye et al., 2012; Mushonga et al., 2015).

In the current study, it was found that a greater proportion of goats slaughtered at Morogoro Municipal slaughterhouse were females as previously reported by Kilumbi and Nonga (2017). This finding is contrary to what has been reported in other countries such as Ethiopia (Negash et al., 2015; Mekuanint et al., 2017; Rwanda (Mushonga et al., 2015) and Kenya (Otsyina et al., 2015). We recommend a study to be done to find out the reasons why females are frequently slaughtered than males and if there is any significant loss associated with slaughtering higher number of females than males' e.g. fetal wastage.

Conclusion

This study found that the ingestion of indigestible foreign bodies is common in goats slaughtered at the Morogoro Municipal slaughterhouse as a result of wide spread use with improper disposal of plastic bags. This may cause significant losses in the livestock production. It is recommended that plastic bags which are commonly used for packaging of various items such as food should be properly disposed of and appropriate policies for solid waste management should be implemented.

Acknowledgement

The authors would like to thank Mr. Shedrack Bwatota for his assistance during data collection.

References

Abutarbush SM, Radostits OM (2004) Obstruction of the small intestine caused by a hairball in 2 young beef calves. *Can Vet Journal* 45: 324-325.

- Atawalna J, Kotoku VA, Ewura S (2015) Prevalence of indigestible foreign materials in small ruminants slaughtered at the Kumasi Abattoir of Ghana. *IJLR* 5: 1-7.
- Baillie S, Anzuino K (2006) Hairballs as a cause of anorexia in Angora goats. *Goat Vet Soc J* 22: 53-55.
- Ban Ismail Z, Al-Majali A, Al-Qudah K (2007) Clinical and surgical findings and outcome following rumenotomy in adult dairy cattle affected with recurrent rumen tympany associated with non-metallic foreign bodies. *American J Animal Vet Sci* 2: 66-71.
- Berrie K, Tadesse E, Mossie B, Anteneh B (2015) Study on rumen and reticulum foreign body in slaughtered cattle at Gondar Elfora abattoir. *World J Biol Med Sci* 2: 133-150.
- Bwatota SF, Makungu M, Nonga HE (2018) Occurrences of indigestible foreign bodies in cattle slaughtered at Morogoro Municipal slaughterhouse, Tanzania. *J Vet Med* 2018: 6.
- Chenyambuga SW, Komwihangilo DM, Jackson M (2012) Production performance and desirable traits of small East African goats in semi-arid areas of central Tanzania. *Liv Res Rural Develop* 24: 118.
- Constable PD, Hinchcliff KW, Done SH, Grünberg W (2017) *Veterinary Medicine: A Textbook of Diseases of Cattle, Horses, Sheep, Pigs, and Goats*, 11th edition. Elsevier, St. Louis.
- Fromsa, A. and Mohammed, N. (2011). Prevalence of indigestible foreign body ingestion in small ruminant slaughtered at Luna Export Abattoir, East Shoa, Ethiopia. *J Anim Vet Adv* 10: 1598-1602.
- Fulton LK, Clarke MS, Farris HE (1994) The goat as a model for biomedical research and teaching. *ILAR Journal* 36: 21-29.
- Ghurashi MAH, Seri HI, Bakheit AH, Ashwag EAM (2009) Effect of surgical removal of foreign body from goat's rumen with special reference to the prevalence of foreign body in goats in southern Darfur. *AJBAS* 3: 664-668.
- Habasha FG, Yassein SN (2014) Advance techniques in traumatic reticuloperitonitis diagnosis: review. *Al-Qadisiya J Vet Med Sci* 13: 50-57.
- Haenlein GFW (2004) Goat milk in human nutrition. *Small Rum Res* 51: 155-163.
- Hozza WA, Mtenga LA, Kifaro GC, Shija DSN, Mushi DE, Safari JG, Shirima EJM (2014) Meat quality characteristics of small East African goats and Norwegian crosses finished under small scale farming conditions. *Asian-Australas J Anim Sci* 27: 1773-1782.
- Igbokwe IO, Kolo MY, Egwu GO (2003) Rumen impaction in sheep with indigestible foreign bodies in the semi-arid region of Nigeria. *Small Rum Res* 49: 141-146.

- Kilumbi LA, Nonga HE (2017) Magnitude of foetal wastage and the monetary losses in sheep and goats slaughtered in Morogoro selected slaughter facilities, Morogoro Tanzania. Proceeding of Tanzania Veterinary Association Scientific Conference, Arusha, 226-231.
- Kumar S, Kumar B, Kumar R, Kumar S, Khatkar SK, Kanawjia SK (2012) Nutritional features of goat milk- a review. *Indian J Dairy Sci* 65: 266-273.
- Löhr CV (2013) One hundred two tumors in 100 goats (1987-2011). *Vet Pathol* 50: 668-675.
- Matika O, Sibanda R, Beff ML (1992) Eruption of permanent incisors in indigenous goats and sheep. Proceedings of the first biennial conference of the African small ruminant research network, Kenya, 499-504.
- Mekuanint S, Alemneh T, Asredie T (2017) Indigestible foreign bodies-causes of rumen impaction in cattle, sheep and goats slaughtered at Addis Ababa Abattoir Enterprise, Ethiopia. *J Vet Sci Med* 5: 5.
- MLFD, Ministry of Livestock and Fisheries Development (2015) Tanzania Livestock modernisation initiative. https://livestocklivelihoodsandhealth.org/wp-content/uploads/2015/07/Tanzania-livestock-modernization-initiative_July-2015.pdf, 2017.
- Mozaffari AA, Vosough D (2007) Idiopathic megaesophagus in a goat: clinical and radiological features. *IJVS* 2: 94-97.
- Mozaffari AA, Olomi MM, Vosough D (2009) Unusual and severe ruminal impaction in a goat-kid: clinical and radiological findings. *IJVS* 4: 115-119.
- Mpanduji DG, Bittegeko SBP, Mgasa MN, Batamuji EK (2000) Analgesics, behavioral and cardiopulmonary effects of epidurally injected medetomidine (Domitor^R) in goats. *J Vet Med A Physiol Pathol Clin Med* 47: 65-72.
- MPEE, Ministry of Planning Economic and Empowerment (2006). Morogoro Region Socio Economic Profile. Dar es Salaam: Ministry of Planning Economic and Empowerment.
- Muhairwa AP, Msoffe PI, Ramadhani S, Mollel EL, Mtambo MMA, Kassuku AA (2007) Prevalence of gastro-intestinal helminthes in free-range ducks in Morogoro Municipality, Tanzania. *Livest Res Rural Dev* 19: 48.
- Muhammad M, Banyigyi SA, Tafarki EA, Ighodalo ET, Benschak J, Asala O, Rimfa A, Ibu JO, Ehizobolo D (2011) Trichobezoar as a cause of anorexia in West African dwarf goat. *Nig Vet J* 32: 362-365.
- Mushonga B, Habarugira G, Musabyemungu A, Udahemuka JC, Jaja FI, Pepe D (2015) Investigations of foreign bodies in the fore-stomach of cattle at Ngoma slaughterhouse, Rwanda. *J S Afr Vet Assoc* 86: 1233.
- NBS, National Bureau of Statistics (2013) 2012 Census Results Tanzania. Dar es Salaam: Government Printing Office.
- Negash S, Sibhat B, Sheferaw D (2015) Post-mortem study on indigestible foreign bodies in the rumen and reticulum of ruminants, Eastern Ethiopia. *Onderstepoort J Vet Res* 82: 881.
- Ng'umbi NH, Kassuku AA, Karimuribo ED, Fitzpatrick J, Smith D, Matiko MK, Kambarage DM (2015) Status of helminthosis and coccidiosis in goats and sheep in traditional flocks in Melela Division, Morogoro region, Tanzania. *TVJ* 30: 19-27.
- Nonga HE, Karimuribo ED (2009) A retrospective survey of hydatidosis in livestock in Arusha, Tanzania, based on abattoir data during 2005-2007. *Trop Anim Health Prod* 41: 1253-1257.
- Nonga HE, Sells P, Karimuribo ED (2010) Occurrences of thermophilic *Campylobacter* in cattle slaughtered at Morogoro Municipal abattoir, Tanzania. *Trop Anim Health Prod* 42: 73-78.
- Onditi SJ, Silayo RS, Kimera SI, Kimbita EN, Mbilu TJNK (2007) Preliminary studies on prevalence and importance of goat trypanosomosis in selected farms in Morogoro District, Tanzania. *Livest Res Rural Dev* 19: 65.
- Otsyina HR, Nguhiu-Mwangi J, Mogoia EGM, Mbuthia PG, OgaraWO (2015) Prevalence of indigestible rumen foreign bodies in sheep and goats at Dagoretti and Kiserian abattoirs, Kenya. *Inter J Vet Sci* 4: 75-80.
- Parish SM, Middleton JR, Baldwin TJ (1996) Clinical mega oesophagus in a goat with thymoma. *Vet Rec* 139:94.
- Peacock C (2005) Goats-a pathway out of poverty. *Small Rum Res* 60: 179-186.
- Tanimotyo T, Ohtsuki Y, Nomura Y (1994) Rumenoabomasal lesions in steers induced by naturally ingested hair. *Vet Pathol* 31: 280-282.
- Tesfaye D, Daba D, Mekibib B, Fekadu A (2012) The problem of environmental pollution as reflected in the fore stomach of cattle: A postmortem study in Eastern Ethiopia. *Global J Environ Res* 6: 61-65.
- Tiruneh R, Yesuwork H (2010) Occurrence of rumen foreign bodies in sheep and goats slaughtered at the Addis Ababa Municipality Abattoir. *Ethiop Vet J* 14: 91-100.
- URT, United Republic of Tanzania (2012) Ministry of Livestock and Fisheries Development Budget Speech 2012/2013. Dar es Salaam: Government Printing Office.
- Wilson RT, Durkin JW (1984) Age at permanent incisor eruption in indigenous goats and sheep in semi-arid Africa. *Livest Prod Sci* 11: 451-455.